

REVIEW ARTICLE

The Treatment of Vital Teeth Affected by Endo-Periopathology with Intra-Bony Defects involving the Apex: A Literature Review

Ruta Geguzyte¹, Benita Vaisvilaite¹, Rita Veberiene¹, Nomeda Baseviciene¹

1- Lithuanian University of Health Sciences, Medical Academy, Faculty of odontology, Department of Dental and Oral Pathology

Abstract

The aim of this article is to investigate scientific literature with cases of vital teeth with radiographically visible intra-bony defects involving the apex and to evaluate current treatment options. This was a literature review of MEDLINE and Cochrane with no time restrictions. Two reviewers performed the data extraction independently using data collection forms. Four clinical case-control studies were found eligible and were included in the literature review. There are three possible treatment options according to the analyzed studies: periodontal treatment after root canal treatment; periodontal treatment only; and extraction and tooth replacement with implant, tooth-supported bridges, or Maryland bridges. The outcomes in all published cases showed a significant improvement in the most parameters regardless of the chosen treatment method. The absence of an accurate method to define pulp vitality complicates treatment selection. Further clinical studies are required to investigate treatment options for vital teeth affected by endo-perio pathology with intrabony defects involving the apex.

Keywords: Endo-perio, perio-endo, endodontic and periodontal, intrabony defects, regenerative treatment

Address for correspondence: Benita Vaisvilaite. Kalnieciu 231-117, LT-50108, Kaunas 50108, Lithuania
Mobile: +37037337552

Introduction

Endo-perio lesions are frequent in daily dentistry. Treatment options have been discussed extensively in the scientific literature. Endo-perio pathology was well described by Simon et al in 1972 ^[1], and these authors classified these cases as follows:

- Primary endodontic lesions
- Primary endodontic lesions with secondary periodontal involvement
- Primary periodontal lesions
- Primary periodontal lesions with secondary endodontic involvement
- Truly combined lesions.

Novel classifications have been offered by various other authors ^[2, 3]. Most are based on the primary disease and secondary effects. Clear guidelines are suggested for treatment of endo-perio cases when the primary disease is diagnosed ^[4,5]. The primary endodontic lesions have to be treated endodontically, and the primary periodontal lesion has to be treated

periodontically^[5]. Treatment of combined lesions depends on the structures involved in the pathology. Root canal treatment is necessary when the pulp is necrotic or previous endodontic treatment is low-quality ^[5]. Periodontal treatment has to be applied first when the primary periodontal lesion is present ^[4]. However, there are some endo-perio cases that are not studied in detail. One of these is vital teeth with radiographically visible intrabony defects involving the apex. These cases are very delicate and require a multidisciplinary approach. Radiographically visible defects reaching the apex indicate the need for endodontic treatment ^[4]. However, a normal reaction to pulp sensitivity testing shows that the endodontium is healthy ^[6]. Treatment options from the endodontic and periodontal prospective usually vary significantly, and it is very difficult to determine a consensus. Moreover, there is a lack of significant scientific literature on this topic. As a result, teeth with this pathology are often called hopeless and rarely treated ^[7]. The aim of this article is to investigate the scientific

literature for details on vital teeth with radiographically visible intra bony defects involving the apex and to determine suggested treatment options.

Materials and Methods

The search strategy covered electronic databases and identified articles published through December 2017. No publication year was set. The electronic databases search was carried out in PubMed (MEDLINE) database and the Cochrane library. The search keywords were: endo-perio, perio-endo, endodontic and periodontal, endo, perio, and intrabony defects. There were 1493 articles identified (Figure 1). The titles identified in the searches were

screened. If the title indicated possible inclusion, then the abstract was evaluated.

After screening, 23 articles were assessed for eligibility; 1027 articles were excluded because their abstracts failed to correspond to the aims of the study. Thus, 23 full-text articles were evaluated; 19 articles were excluded because they did not meet the inclusion criteria: clinical studies (case report, case series, clinical studies), vital tooth (teeth), radiographically visible intrabony defects involving the apex. Two reviewers working independently from one another assessed all the citations. The studies were selected for inclusion if they fulfilled all of the above criteria. Thus, four articles were selected for the study.

Figure 1 Prisma Flow Chart showing the process of search and selection of articles included in this study.

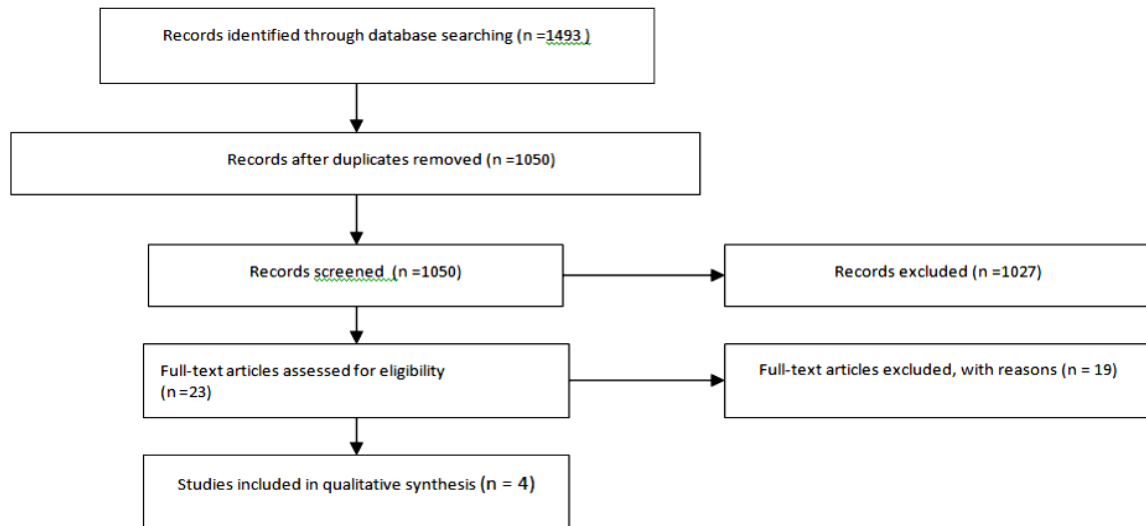


Figure 2. Treatment options, follow-up time and outcome of the cases presented in selected studies

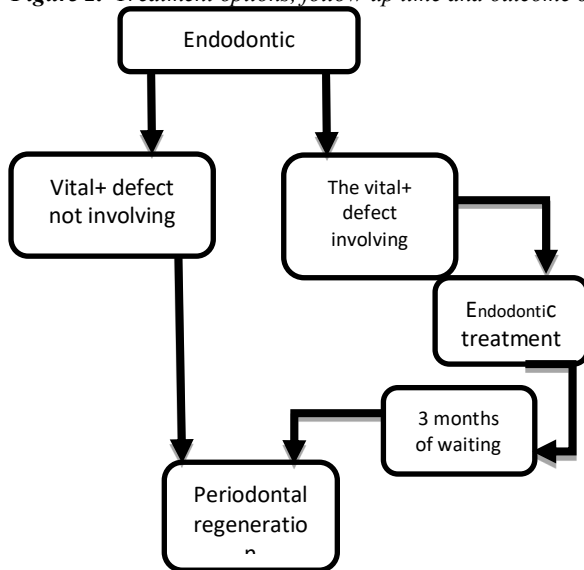


Table 1 Treatment options, follow-up time, and outcome of the cases presented in selected studies

Author, Year	Condition before treatment	Endodontic treatment	Periodontal treatment	Follow-up time	Outcome
Zehnder M et al, 2002 [4]	- Tooth 26, intrabony defect involving the apex of the MB root; vital tooth - Tooth 31, intrabony defect involving the apex; vital tooth	- - - -	Surgical debridement + periodic non-surgical periodontal maintenance Surgical debridement + periodic non-surgical periodontal maintenance over 3-4 month intervals	18 years - - - 3 years	6 mm clinical attachment level (CAL) gain in furcation area; vital tooth 5 mm CAL gain on the distal aspect of the tooth; vital tooth
Cortellini P et al, 2011 [8]	-12 teeth with intrabony defects beyond the apex; vital teeth -24 “hopeless” teeth extracted and replaced with implants (14), tooth supported bridges (8), and Maryland bridges (2)	- + - - - -	Surgical debridement + periodontal regeneration - - - -	- 5 years - - - 5 years	- 6.6 ± 2.1 mm CAL gain - - - - Abutment teeth of eight tooth supported bridges and Maryland bridges PPD ≤3 mm; radiographic bone level covering the first implant thread
Eun-Young Kwon et al, 2013 [9]	-Tooth 14, intrabony defect involving the apex; vital tooth - - - - -Tooth 36, intrabony defect involving the apex of the D root; vital tooth - -Tooth 37, intrabony defect involving the apex of the D root; vital tooth	- + - - - - + - - +	Surgical debridement+ periodontal regeneration - - - - Surgical debridement+ periodontal regeneration - - - Surgical debridement + periodontal regeneration	- 1 year - - - 9 month - - - 6 month	Remarkable enhancement of the bone density around the affected region - The significant bone filling around the distal aspect of the distal root - Remarkable osseous repair and enhanced radiopacity
De Sanctis M et al, 2013 [10]	137 teeth with intrabony defects extending to or involving the apex	- -	-47 teeth treated with surgical debridement + guided tissue regeneration (GTR) - -34 teeth treated with surgical debridement + enamel matrix derivative (EMD) - -56 teeth treated with surgical debridement + EMD + bone substitute	- - - - 7 to 18 years	4.9 ± 1.0 mm CAL gain; 1 non-vital tooth - - - 4.26 ± 1.4 mm CAL gain; vital teeth - - 5.36 ± 0.7 mm CAL gain; 4 non-vital teeth

Results

There are three treatment options for treating vital teeth affected by endo-perio pathology with intrabony defects involving the apex suggested in the selected articles:

These treatment options are described in more detail below in

- Periodontal treatment after root canal treatment
- Periodontal treatment only
- Extraction and replacement with implant, tooth supported bridges or Maryland bridges

Periodontal treatment after root canal treatment

Deep periodontal intrabony lesions with secondary endodontic involvement usually occur when the progression of a periodontal pocket reaches the periapical tissues [11]. The primary periodontal lesions with secondary endodontic involvement generally end up with pulpal irritation as they progress apically and the pulp remains vital [1]. This is because when pathologic changes occur in the pulp tissue influenced by destructive periodontal disease, the pulp usually does not undergo necrosis as long as the main canal is not affected [13]. Periodontal regenerative treatment is one of the treatment suggestions for these cases [4, 8-10]. Periodontal regeneration seems to be effective in the treatment of one-, two- and three-wall intrabony defects or in combinations of deep and shallow defects. It can also be used in both wide and narrow defects [12]. Most articles claim that a growing amount of evidence indicates that periodontal regeneration can result in long-term retention of teeth with deep intra-bony defects [13-16]. The only problem is that there are only a few studies analyzing the treatment of vital teeth affected by endo-perio pathology with intrabony defects involving the apex [4, 8-10]. Analyzing treatment recommendations for these cases, the authors suggest endodontic treatment for at least three months before surgery (Figure 2).

Periodontal treatment only

There is an opposite opinion that even extensive endo-perio pathology with apex involvement and vital pulp should be managed only with periodontal therapy [10]. From the endodontic prospective, if the tooth is vital, then endodontic

treatment would not have any impact on the process of healing and is unnecessary [10].

There are studies stating that most teeth with extensive periodontal disease showed pathological changes in the pulp [17]. In these cases, the pulp remains vital even when bacteria from the periodontium start to invade the structure of the tooth through possible pathways connecting the endodontic and periodontal tissues [17-20]. There are multiple branches connecting the main root canal system with the periodontal ligament: furcated, collateral, lateral, secondary, accessory, intercanal and reticular canals [20]. These accessory canals, as well as dentinal tubules [20], are the main possible pathways for the infection to spread from infected periodontium to the healthy pulp. However, from the endodontic prospective, these are not the indications for endodontic treatment.

As long as the pulp remains vital and the main blood supply is intact, then endodontic treatment can be considered overtreatment. Healthy pulp restricts the diffusion of bacteria and microorganisms as they invade the dentinal tubules of devitalized teeth more than the tubules of the vital tooth [21]. Endodontic treatment should be performed only when there are signs of irreversible pulp changes or necrosis. There are some publications opposing this opinion, and they tend to do endodontic treatment prior to periodontal phase [8, 4] only for prophylaxis. Monitoring of the pulp vitality should be performed continuously during treatment with endo-perio compromised teeth. Endodontic treatment should only be performed when there are symptoms of irreversible pulp changes and necrosis. This treatment option was investigated in detail by de Sanctis et al., (2013) [10]. They studied 137 patients with vital teeth and isolated angular bony defects reaching the apical third of the root length. The subjects were treated only with guided tissue regeneration. At a recall time of 7 to 18 years, only 5 teeth were found to be non-vital [10].

Tooth extraction and implant placement

The literature suggests that periodontal regeneration is a sensitive technique and is burdened by a significant amount of clinical failures or incomplete success [12, 22]. Therefore, extracting and replacing a hopeless tooth with an implant is a good alternative. It requires less

time to see the results, and it is more predictable than periodontal regeneration. In cases with the huge alveolar bone loss, a highly skilled and knowledgeable is needed. Cortellini et al. stated that implant therapy was successful over 5 years in replacing hopeless extracted teeth with deep primary periodontal lesions involving periapical tissues^[8].

Discussion

We reviewed treatment options for vital teeth affected by endo-perio pathology with intrabony defects involving the apex. There are three options: extraction and implant placement; periodontal treatment only; and combined endodontic and periodontal treatment. The two latter options save the natural tooth and were reviewed further (Table 1). In 2 out of 4 reviewed articles (15 teeth in total)^[8, 9], endodontic treatment was performed prior to the periodontal phase (surgical debridement and periodontal regeneration). Follow-up time varied from 0.5 to 5 years; all cases showed healing. Only periodontal treatment was performed in two out of the four^[4, 10] reviewed articles (139 teeth in total). The follow-up time varied from 3 to 18 years. Healing was obtained in all cases. All cases had healed, and thus both treatment options are feasible. However, we note that follow-up time and assessment of outcomes varied markedly for the initial situation.

These endo-perio cases are often called hopeless, and most teeth are extracted. A tooth that is maintained in the mouth could be considered a positive outcome. The present scientific literature on this topic is inconsistent some of the cases seem to be occasional and do not show reliable protocols. There is a lack of high-level scientific evidence on this topic, but the hypothesis is that endodontic treatment does not affect the treatment outcomes of vital teeth with bony defects reaching the apical third of the root length.

The need for endodontic treatment is usually decided after assessment of the pulp vitality. There is a consensus and reasonable amount of scientific evidence that a vital tooth cannot cause periapical pathology and root canal treatment cannot affect the healing. The problem is that there are no scientifically approved methods to define and measure pulp vitality.

Some experimental methods are being tested (pulse oximetry, laser doppler flowmetry)^[23] but they are not approved to be used clinically. To date, the gold standard methods are pulp sensibility tests^[24]. The most commonly used assay is the cold test, but it has many limitations: It does not indicate the exact histological state of the pulp and the responses might be unreliable in traumatized teeth (acute or orthodontic trauma), immature teeth with open apices, older patients with calcified pulp cavity, or teeth with extensive restorations^[24]. The tests totally rely on a patient's response, and results are difficult to administer/compare^[24]. The most important issue in endo-perio cases is that it is impossible to assess pulp vitality in different parts of the pulp with pulp sensitivity tests, i.e., in multirouted teeth or coronal/intracanal pulp. Even if the tooth shows a normal reaction to pulp sensitivity tests, it is possible that there is irreversible pulpitis or necrosis in some parts of the pulp tissue. If there is a false positive for pulp sensitivity testing, then endo-perio lesions with endodontic infection but without endo treatment might cause a delay in periodontal healing. If we have a false negative response, then endodontic treatment could be considered overtreatment. This is a big issue in modern today's dentistry. In the age of minimally invasive endodontics, avoiding endo therapy when possible is the most minimally invasive.

Conclusion

There is a lack of scientific evidence regarding treatment possibilities for teeth affected by endo-perio pathology with intra bony defects involving the apex. According to this study, the clinician has three options: periodontal regeneration after endodontic treatment; periodontal regeneration without endodontic treatment; and implant placement. All of these treatment strategies show good long-term results. Each treatment option is technically sensitive and requires a skilled and knowledgeable operator. However, there are no clear guidelines for choosing a treatment plan. The absence of an accurate method to define pulp vitality complicates the treatment selection. Further clinical studies are needed to investigate treatment options for vital teeth affected by

endo-perio pathology with intrabony defects involving the apex.

Acknowledgments

We want to thank Prof. Vita Machulskiene for comments that greatly improved the manuscript.

Conflict of Interest: None declared

Source of Support: Nil

References

1. Simon JH, Glick DH, Frank AL. The relationship of endodontic-periodontic lesions. *J Clin Periodontol.* 1972; 43: 202.
2. Torabinejad M, Trope M. Endodontic and periodontal interrelationships. *Principles and Practice of Endodontics*, R. E. Walton and M. Torabinejad, Eds., 1996.
3. Armitage GC. Development of a classification system for periodontal diseases and conditions. *Annals of Periodontology*, 1999; 4(1): 1–6.
4. Zehnder, M., Gold, S. I. And Hasselgren, G. Pathologic interactions in pulpal and periodontal tissues. *J Clin Periodontology* 2002; 29: 663–6714.
5. Gupta S, Tewari S, Tewari S, Mittal S. Effect of the time lapse between endodontic and periodontal therapies on the healing of concurrent endodontic-periodontal lesions without communication: A prospective randomized clinical trial. *J Endod.* 2015; 41(6): 785-90.
6. Jafarzadeh H, Abbott PV. Review of pulp sensibility tests. Part I: general information and thermal tests. *Int Endod J.* 2010; 43(9):738-62.
7. Singh P. Endo-Perio Dilemma: A Brief Review. *Dental Research Journal.* 2011; 8(1): 39-47.
8. Cortellini P, Stalpers G, Mollo A, Tonetti Ms: Periodontal regeneration versus extraction and prosthetic replacement of teeth severely compromised by attachment loss to the apex: 5-year results of an ongoing randomized clinical trial. *J Clin Periodontol* 2011; 38: 915–924.
9. Kwon Ey, Cho Y, Lee Jy, Kim Sj, Choi J. Endodontic treatment enhances the regenerative potential of teeth with an advanced periodontal disease with secondary endodontic involvement. *J Periodontal Implant Sci.* 2013; 43(3):136-40.
10. De Sanctis M, Goracci C, Zucchelli G. Long-term effect on tooth vitality of regenerative therapy in deep periodontal bony defects: A retrospective study. *Int J Periodontics Restorative Dent.* 2013; 33(2):151-7.
11. Roststein I, Simon James H.S. Diagnosis, prognosis and decision-making in the treatment of combined periodontal-endodontic lesions. *Periodontol 2000* 2014; 34, 165-203.
12. Cortellini P, Tonetti Ms. Clinical concepts for regenerative therapy in intrabony defects. *Periodontol 2000* 2015; 68: 282-307.
13. Cortellini P, Tonetti Ms. Long-term tooth survival following regenerative treatment of intrabony defects. *J Periodontol* 2004; 75(5): 672-8.
14. Sculean A, Kiss A, Miliauskaite A, Schwarz F, Arweiler Nb, Hannig M. Ten-year results following treatment of intra-bony defects with enamel matrix proteins and guided tissue regeneration. *J Clin Periodontol* 2008; 35(9): 817-24.
15. Pretzl B¹, Kim Ts, Steinbrenner H, Dörfer C, Himmer K, Eickholz P. Guided tissue regeneration with bio absorbable barriers III 10-year results in infrabony defects. *J Clin Periodontol.* 2009; 36(4): 349-56
16. Nygaard-Ostby P, Tellefsen G, Sigurdsson Tj, Zimmerman Gj, Wikesjo Ume. Periodontal healing following reconstructive surgery: effect of guided tissue regeneration. *J Clin Periodontol* 1996; 23: 1073-1079.
17. Gautam S, Galgali Sr, Sheethal Hs, Priya Ns. Pulpal changes associated with advanced periodontal disease: A histopathological study. *J Oral Maxillo fac Pathol.* 2017; 21(1): 58-63.
18. Langeland K, Rodrigues H, Dowden W. Periodontal disease, bacteria, and pulpal histopathology. *Oral Surg Oral Med Oral Pathol.* 1974; 37(2): 257-70.
19. Czarniecki RT, Schilder H. A histological evaluation of the human pulp in teeth with varying degrees of periodontal disease. *J Endod.* 1979; 5(8):242-53.
20. Sunitha V R, Emmadi P, Namasivayam A, Thyegarajan R, Rajaraman V. The periodontal - endodontic continuum: A review. *J Conserv Dent.* 2008; 11(2): 54-62.
21. Nagaoka S, Miyazaki Y, Liu Hj, Iwamoto Y, Kitano M, Kawagoe M. Bacterial invasion into dentinal tubules of human vital and nonvital teeth. *J Endod* 1995; 21: 70–73.
22. Sanz M, Tonetti M. S, Zabalegui I, Sicilia A, Blanco J., Rebelo H., (2004) Treatment of intrabony defects with enamel matrix proteins or barrier membranes: Results from a multicenter practice- based clinical trial. *J Clin Periodontology* 75, 726–733.
23. Alghaithy Ra, Qualtrough Aj. Pulp sensibility and vitality tests for diagnosing pulpal health in permanent teeth: a critical review. *IntEndod J.* 2017; 50(2): 135-142.
24. Jafarzadeh H, Abbott Pv. Review of pulp sensibility tests. Part I: general information and thermal tests. *IntEndod J.* 2010; 43(9): 738-62.