

ORIGINAL ARTICLE

Spectrum of Lesions in Hysterectomy Specimens and their Preoperative Correlation

Khunte VP¹, Kulkarni V², Gahine R³, Indoria CS⁴

1. Assistant Professor, Department of Obstetrics and Gynaecology, Govt. Medical College, Rajnandgaon.
2. Assistant Professor, Pathology Department, Pt JNM Medical College, Raipur.
3. Director and Professor, Pathology Department, Pt JNM Medical College, Raipur.
4. Assistant Professor, Pathology Department, Govt. Medical College, Rajnandgaon.

Abstract

Hysterectomy is the commonest major gynaecological procedure performed throughout the world. It can be done by abdominal or vaginal routes. Hysterectomy is an effective treatment option for many conditions like fibroid, abnormal uterine bleeding, endometriosis, adenomyosis, uterine prolapse, pelvic inflammatory disease, cancers of the reproductive tract. This study was undertaken to identify the most common histopathological lesions in hysterectomy specimens and to correlate the findings with clinical indications and radiological features.

Keywords: Hysterectomy, Histopathology, Fibroids

Address for correspondence: Dr. Vishal Kulkarni, Assistant Professor, Pathology Department, Pt JNM Medical College, Raipur. E-mail: kulkarnivishal1978@gmail.com

Received on:05/11/2017 Revised:11/11/2017 Accepted: 16/11/2017

Introduction

Hysterectomy is the commonest major gynaecological procedure performed throughout the world. In India, it accounts for 06% of all surgeries. Hysterectomy rate varies from place to place depending upon patient and clinical factors. This study was conducted with an aim to get an insight into the pattern of lesions in hysterectomy specimens in this region. Abdominal removal of the uterus is total abdominal hysterectomy, and supracervical is the subtotal hysterectomy.^[1] Charles Clay performed the first subtotal hysterectomy in Manchester, England in 1843 and the first total was performed in 1929.^[2] Hysterectomy is an effective treatment option for many conditions like fibroid, abnormal uterine bleeding, endometriosis, adenomyosis, uterine prolapse, pelvic inflammatory disease, cancers of the reproductive tract.^[3]

Materials and Methods

The present study was carried out in the Department of Pathology, Government Medical College, Rajnandgaon from January 2016 till July 2017. A total of 358

hysterectomy specimens were received in the department, out of which 352 were included in the study. Clinical information was obtained regarding patient's age, presenting symptoms, sonography findings and a clinical indication of hysterectomy. Representative sections were processed by standard histopathological technique, stained with Hematoxylin & Eosin stain and examined microscopically.

Results

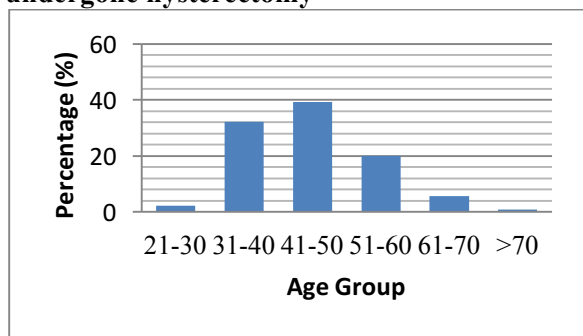
A total of 352 hysterectomy specimens were studied between January 2016 and July 2017. The clinical presentations, indications, age distribution, type of hysterectomy and histopathological diagnosis and its correlation are summarized in following tables and charts.

Histomorphology of Myometrial Lesions: In 41% cases no specific pathology was observed. In 28% cases, Leiomyoma was seen. Adenomyosis was observed in 19% cases. In 8% cases, Adenomyosis with follicular cyst was seen. In 4% cases, Leiomyoma with adenomyosis was observed.

Histopathological Diagnosis of Cervical Lesions: In all the cervical lesions, 61% was squamous cell carcinoma. Chronic nonspecific

cervicitis was 17%. Nonspecific pathology and follicular cervicitis were 7% each. 3% each was adenocarcinoma and papillary endocervicitis. 2% was cervical interepithelial neoplasia.

Chart No 01: Age distribution of patients undergone hysterectomy



Histopathological Diagnosis of Ovarian Lesions: 72% were the follicular cyst. 8% were corpus luteal cyst. 5% each were serous cystadenoma and mucinous cystadenoma. 3% each were mucinous cystadenocarcinoma,

thecoma, and teratoma. 2% was serous cystadenocarcinoma.

Chart No 02: Histopathological Diagnosis of Endometrial Lesions

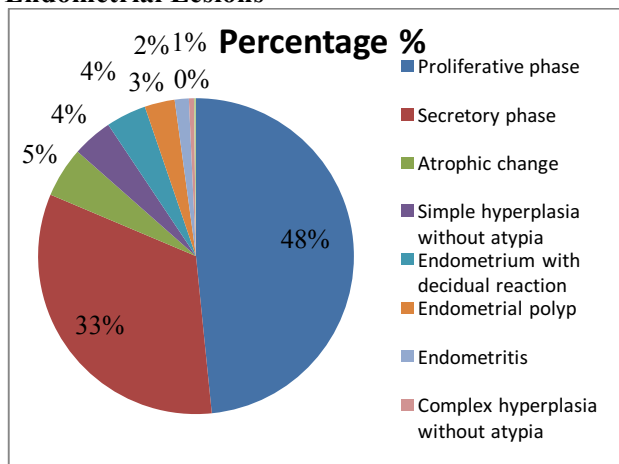


Table No 01: Clinical presentation of patients subjected to hysterectomy

Clinical presentation	Number of patients	Percentage (%)
Irregular bleeding	89	25
Menorrhagia	68	19
Uterovaginal Prolapse	57	16
Pain in abdomen	50	14
White discharge	50	14
Dysmenorrhea	38	10

Table No. 02: Clinical Indications of Hysterectomy

Indication	No. of cases	Percentage (%)
Fibroid	146	41.5
Irregular Uterine bleeding	79	22.5
Uterovaginal prolapse	66	18.9
Pelvic inflammatory disease	18	5.1
Endometrial hyperplasia	18	5.1
Endometrial polyp	13	3.7
Ovarian mass/cyst	8	2.2
Carcinoma cervix	3	0.8
Carcinoma Endometrium	1	0.2
Total	352	

Table No 03: Types of hysterectomy

Types of hysterectomy	Number of cases	Percentage (%)
Total abdominal hysterectomy with bilateral salpingoopherectomy	203	57
Total abdominal hysterectomy	65	18
Vaginal hysterectomy	60	17
Total abdominal hysterectomy with unilateral salpingoopherectomy	20	5.6
Subtotal hysterectomy	04	1.1

Types of hysterectomy: Total abdominal hysterectomy with bilateral salpingoophorectomy was done in 57% cases. Total abdominal hysterectomy was done in 18% cases. Vaginal hysterectomy was done in 17% cases. Total abdominal hysterectomy with unilateral salpingoophorectomy was done in 5.6 cases. Subtotal hysterectomy was done in 1.1% cases.

Table No 04: Pattern & Frequency of Pathologies Identified in 352 Hysterectomy Cases

Histopathology Identified	No. of cases	Percentage (%)
Leiomyoma	63	18
Leiomyoma with chronic cervicitis	35	10
Adenomyosis	53	15
Adenomyosis with chronic cervicitis	15	4.2
Leiomyoma with Adenomyosis	15	4.2
Endometrial hyperplasia	18	5
Endometrial polyp	13	3
Endometrial carcinoma	01	0.2
Chronic cervicitis	71	20
Cervical intraepithelial neoplasia	18	5
Cervical polyp	08	2.2
Carcinoma cervix	03	0.8
Adenomyosis with Functional Ovarian cyst	31	8
Serous cystadenoma	02	0.5
Serous cystadenocarcinoma	01	0.2
Mucinous cystadenoma	02	0.5
Mucinous cystadenocarcinoma	01	0.2
Mature Teratoma	01	0.2
Thecoma	01	0.2
Total	352	

Table No 05: Correlation of Clinical Diagnosis with Histopathological Diagnosis

	Preoperative Clinical diagnosis	Total histopathological diagnosis	Preoperative Radiological diagnosis	Discordance with Radiological diagnosis
Leiomyoma	47	98	89	09
Adenomyosis	26	68	12	56
Endometrial hyperplasia	00	06	06	00
Endometrial polyp	03	10	10	00
Endometrial carcinoma	00	01	00	01
Cervical intraepithelial neoplasia	00	19	00	19
Cervical polyp	08	08	08	00
Carcinoma Cervix	00	03	00	03
Serous cystadenoma ovary	00	02	02	00
Serous cystadenocarcinoma ovary	00	01	00	01
Teratoma	00	01	01	00
Thecoma	00	01	00	01
Mucinous cystadenoma ovary	00	01	01	00
Mucinous cystadenocarcinoma ovary	00	01	00	01
Adenomyosis with Functional Ovarian cyst	00	20	20	00

Discussion

The present study included 352 hysterectomy cases over a period from January 2016 to July 2017. The data regarding the patient's age, clinical diagnosis, indication, type of hysterectomy and histopathological diagnosis were reviewed and compared.

The commonest estimated age range of hysterectomy in the present study is 41-50 years which is similar to that of other studies. [4,5,6,7] Among hysterectomies majority were done through abdominal route 83 %, and 17% cases were done through vaginal route. Similar was seen in studies of [7,8,9] The vaginal route has increasingly become the method of choice for hysterectomy. Contraindications of vaginal hysterectomy were usually considered as nulliparity, history of pelvic surgery and excessive uterine size. These criteria have greatly impeded the use of vaginal route and supported a high frequency of abdominal and laparoscopically assisted hysterectomy in women without prolapse. [10]

Most common indication for hysterectomy was abnormal uterine bleeding (41%) and fibroid uterus (22.5%) in the present study. Many studies have reported abnormal uterine bleeding as the most common clinical indication for hysterectomy [11-16] whereas others have reported fibroid to be the commonest indication. [4, 17]

The Most common diagnosis was fibroid uterus in 25% hysterectomy specimens. Uterine fibroids are the most common tumors found in women of reproductive age group. [18] Leiomyoma is the most common myometrial lesion in the present study and the same is true for other studies. [12,16,19] It was correlated well with radiology with 90% correlation.

Next most common histopathological diagnosis was Adenomyosis (19%). Adenomyosis is less commonly diagnosed preoperatively and is still largely underdiagnosed as it has no specific symptoms of its own. [20] It was correlated with radiology in only 17% cases, as adenomyosis is usually diagnosed after hysterectomy by histopathological examination as incidental findings. Few cases (3.9 %) in this study revealed the presence of both leiomyoma and adenomyosis. Other studies have also reported this association. [5,6,10,15,21]

The commonest endometrial finding observed in the present study was proliferative phase endometrium followed by secretory phase. Thirty-two percent cases showed atrophic changes. Endometrial hyperplasia constituted 4.5 % cases in the present study which correlated 100% with radiology. Only a sole case of endometrial carcinoma was detected which was radiologically missed.

The Most common ovarian finding was the follicular cyst in 7.9 % hysterectomy specimens. Similar results were reported in other studies. [6,8,10,22] The incidence of ovarian tumors in the present study is close to that reported by Talukder [15]. Benign ovarian cysts correlated well with radiology 100%.

Most common finding in the cervix was chronic non-specific cervicitis in 29 % hysterectomy specimens. Chronic cervicitis is extremely common conditions in adult females have been detected by other authors too. [15] Nineteen (19) cases of Cervical Intra Epithelial Neoplasia were noted in the present study. Three cases of malignant tumors of the cervix were detected in the present study. This incidence is close to that reported by Treloar et al; [23] Polyps of the cervix and endometrium correlated well clinically and with radiology having both correlations of 100%.

Conclusion

The present study indicates the importance of histopathological diagnosis of all hysterectomy specimens which needs to be mandatory as few lesions are purely incidental. The study also provides an insight for correlation of preoperative diagnosis of lesions with histopathology.

Conflict of Interest: None declared

Source of Support: Nil

Ethical Permission: Obtained

References

1. Clayton RD. Hysterectomy. Best practice & Research. Clinical Obstet Gynecol 2006;20:73-87 .
2. John A, Rock MD, Jhon D, Thompson MD; Telinds's Operative Gynaecology. Edition Lippincott- Raven place.

3. Nausheen F, Iqbal J, Bhatti FA, Khan AT, Sheikh S (2004) Hysterectomy The patient's perspective. *Annals* 10:339-341.
4. Adelusola KA, Ogunniyi SO. Hysterectomies in Nigerians: Histopathological Analysis of Cases Seen in Ile Ife. *Niger Postgrad Med J* 2001; 8 (1): 37-40
5. Sarfraz T, Tariq H. Histopathological findings in menorrhagia - A study of 100 hysterectomy specimens. *Pak J Pathol*2005; 16 (3): 83-85
6. Perveen S, Tayyab S. A clinicopathological review of elective abdominal hysterectomy. *J Surg Pak* 2008; 13 (1): 26-29
7. Gousia Rahim Rather, Yudhvir Gupta, Subash Bardhwaj. Patterns of Lesions in Hysterectomy Specimens: A Prospective Study. *J K science* Vol. 15 No.2, April - June 2013
8. Deepti Verma, Pankaj Singh, Rupita Kulshrestha. Analysis of histopathological examination of the hysterectomy specimens in a north Indian teaching institute. *International Journal of Research in Medical Sciences*.Int J Res Med Sci. 2016 Nov;4(11):4753-4758
9. Begum A, Khan R, Nargis N. Comparative study on the specimen of Hysterectomy. *Bangladesh Journal of Medical Science* 2016;15(03).
10. Aubert Agostini et al. Vaginal hysterectomy in nulliparous women without prolapsed: A prospective comparative study. *Br. J. Obstet. Gynecol* 2003 (May); 110: 515-518.
11. Shakira Perveen, SubhanaTayyab. A Clinicopathological Review of elective Abdominal Hysterectomy *Journal of Surgery Pakistan* 2008;13(1).
12. Jamal S, Baqai S. A clinicohistopathological analysis of 260Hysterectomies.*Pak J Pathol*2001;12 (2): 11-14
13. Gupta G, Kotasthane DS, Kotasthane VD. Hysterectomy: A clinic-pathological correlation of 500 cases. *Internet J Gynaecol Obstetrics* 2010; 14 (1): 1-6.
14. Sobande AA, Eskander M, Archibong EI, DamoleIO Elective hysterectomy: A clinicopathological review from Abha Catchment Area of Saudi Arabia. *West Afr J Med* 2005; 24 (1): 31-35.
15. Talukder SI, Haque MA, Huq MH, Alam MO, Roushan A, Noor Z, Nahar K. Histopathological analysis of hysterectomy specimens. *Mymen singh Med J* 2007; 16 (1): 81-84
16. Shergill SK, Shergill HK, Gupta M, Kaur S. Clinicopathological study of hysterectomies. *J Indian Med Assoc*2002; 100 (4): 238-39
17. Jaleel R, Khan A, Soomro N. Clinicopathological study of abdominal hysterectomies.*Pak J Med Sci*2009; 25 (4): 630-34
18. Parker WH. Etiology, symptomatology, and diagnosis of uterine myomas. *J Reproductive Med* 2007; 87: 725-36
19. Abdullah LS. Hysterectomy: A Clinicopathologic correlation. *Bahrain Medical Bulletin* 2006; 28 (2): 1-6.
20. Weiss G, Maseelall P, Schott LL, Brockwell SE, Schocken M, Johnston JM. Adenomyosis a variant, not a disease? Evidence from hysterectomised menopausal women in the study of Women's Health Across the Nation (SWAN). *Fertil Steril* 2009; 91 (1): 201-6
21. Bukhari U, Sadiq S. Analysis of the underlying pathological lesions in hysterectomy specimens. *Pak J Pathol*2007; 18(4): 110-12
22. Jha R, Pant AD, Jha A, Adhikari RC, Sayami G. Histopathological analysis of hysterectomy specimens. *J Nepal Med Assoc* 2006; 45 (163): 283-90.
23. Treloar SA, Do KA, O'Connor VM, O'Connor DT, Yeo MA, Martin NG. Predictors of hysterectomy: an Australian study. *Am J Obstet Gynecol* 1999; 180: 945-54.