ORIGINAL ARTICLE ANATOMY

Journal of Contemporary Medicine and Dentistry
www.jcmad.com

ISSN [P-2347-4513]
ISSN [O-2349-0799]
Year: 2021, Volume: 9
Issue: 1, p: 10 - 14

A Study of Morphological Variations of the Plantaris Muscle

Prerna Neeraj Gupta [1], Neeraj Gupta [2]

1. Assistant Professor, Department of Anatomy, Prathima Institute of Medical Sciences, Naganoor, Karimnagar
2. Assistant Professor, Department of Forensic medicine and Toxicology, Prathima Institute of Medical Sciences, Naganoor, Karimnagar, Telangana, India

Abstract

Background: *Plantaris muscle is made of a small thin muscle belly and long slender tendon. It forms the part of a superficial group of muscles in the posterior compartment of the calf. Agenesis of plantaris muscle can affect the dynamics of the knee. We in the current study tried to determine the variations in the origin and insertion of muscle with a percentage of the absence of plantaris muscle.* ***Methods:*** *Human Adult cadavers were already preserved by the standard method of embalming for dissection. After the dissection of the popliteal fossa followed by dissection of the superficial compartment of the calf muscles, careful dissection was done for the isolation of the plantaris muscle, the muscle was identified and traced from its origin to its insertion with blunt dissection and when required with the fine dissection keeping other related structures like muscles, vessels, and nerves intact.* ***Results****: Total number of specimens was n=50 study. The tendon is inserted into the calcaneum medial to the Achilles tendon in 33 out of 48 lower extremities examined, an incidence of 68.75% the most common type of insertion. The common type of origin was type 2 where the muscle was originated from the following sites, the popliteal surface of the supracondylar ridge, oblique popliteal ligament, and thin bundle of fibers from the posterior part of the capsule of the knee joint in 14 of 48 limbs, an incidence of 29.16%. The incidence of agenesis was 4%.* ***Conclusion:*** *The plantaris muscle and its tendon are subject to considerable variation in both the points of origin and insertion. The genesis of the plantaris muscle was seen bilaterally of a male cadaver, an incidence of 4%. Interdigitations with the lateral head of gastrocnemius (2.1%) and extension of few muscle fibers to the lateral patellar ligament (4.16%) encountered in the present study are less frequent but important variations to be considered for differential diagnosis in PFPS [Patellofemoral pain syndrome] related pains.*

Keywords*: Plantaris Muscle Morphological Variations, Origin, Insertion*

Address for correspondence: Dr. Neeraj Gupta, Assistant Professor, Department of Forensic medicine and Toxicology, Prathima Institute of Medical Sciences, Naganoor, Karimnagar, Telangana, India. Email: neeraj1982sep@gmail.com

Date of Acceptance: 22/12/2020

Introduction

The plantaris muscle also means the sole. It is a small fusiform muscle with a long slender tendon, is of great importance in both anatomical and surgical aspects. [1] From the evolutionary point of view Cruveilhier first proposed the muscle to be a vestige in man, believing that as our evolutionary ancestors assumed an erect posture, the plantaris lost its original attachment to the bottom of the foot (*plantar aponeurosis*) and gained a secondary attachment to the *calcaneum* bone of the heel. [2] During the progress of postural change, the human foot has become man's sole organ of support. [3] The plantaris muscle is absent in only 10% of the individuals. [4] It is also called a freshman's nerve because of the long, slender-

white tendon which is often confused as a nerve by beginners. [5] The plantaris now appears to be a highly specialized sensory muscle; the tendon serves a proprioceptive function that provides a kinesthetic sense of limb position and muscle contraction. In general, most small muscles of the body produce fine adjustments in the movement of larger muscles. [6] Many small, short muscles have been found to act across joints in parallel with much larger muscles, just like the plantaris and triceps surae. The plantaris muscle has been given little attention in the review of the literature. It is commonly mentioned only when absent from a specimen. The plantaris muscle has got highly variable anatomy like fibrous extensions to the patella, which may influence knee function, stability, injury, and rehabilitation. The genesis of the plantaris muscle may affect the dynamics of the knee. [7] The plantaris muscle has its importance in diagnosing the pain associated conditions of the knee, because there are reported cases of unilateral double plantaris [8] firm connection of the plantaris tendon with the Achilles tendon at its mid-portion [9] and an additional tendinous origin of the plantaris muscle and its entrapment between the tibial nerve and its branch to soleus. [10] The plantaris is an important muscle for the proprioceptive sense carrying to the central nervous system, also an important tendon for different types of reconstructive and other related plastic surgeries. Hence the knowledge of its tendon length, breadth, and thickness will be very much useful to plan for the tendon grafting. We in the current study tried to determine the pattern of origin and insertion of muscle and estimate the absence of plantaris muscle and its significance.

Materials and Methods

This study was carried out in the Department of Anatomy, Prathima Institute of Medical Science, Naganoor, Karimnagar. Human Adult cadavers were already preserved by the standard method of embalming for dissection. After the dissection of the popliteal fossa followed by dissection of the superficial compartment of the calf muscles, careful dissection was done for the isolation of the plantaris muscle, the muscle was identified and traced from its origin to its insertion with blunt dissection and when required with the fine dissection keeping other related structures like muscles, vessels, and nerves intact. The morphology and the variations in origin and insertion were noted and documented. The length, breadth, and thickness of the muscle and tendon were measured using Vernier's calipers and with the help of thread and measuring scale. The point of the measurement taken for the muscle is from its origin to the myotendinous junction and for the tendon is from the myotendinous junction to its distal attachment. The selected photographs were taken with the Nikon Coolpix digital camera. The statistical analysis was carried out by using the SPSS 19 Software and the results have been tabulated and represented in the form of tables.

Results

The total n=25 adult cadavers studied of which n=23 were males and n=2 were females, out of these there were n=25 left and n=25 right limbs each belonging to the same gender. After dissecting the specimens, we could find different types of origin and insertion, accordingly, it is observed that the insertion of the tendon is of five types, and the origin of the muscle belly is of six types. The total number of specimens was n=50 out of which n=2(agenesis) n=48 specimens for study.

Types of Insertions

***Type-1*:** The tendon is inserted into the calcaneum medial to the Achilles tendon in 33 out of 48 lower extremities examined, an incidence of 68.75% the most common type of insertion we have encountered.

***Type-2*:** The tendon near its insertion thinned out laterally to form a fan-shaped expansion which is inserted into the calcaneum superficial to the Achilles tendon in 5 out of 48, an incidence of 10.41%.

***Type-3*:** The tendon near its insertion thinned to form a fan-shaped expansion which is inserted into the calcaneum deep to Achilles tendon in 2 of 48 limbs, an incidence of 4.16%.

Type-4: In this type of insertion the tendon is deep to the Achilles tendon; besides few slips from the tendon are attached to the flexor retinaculum in 2 of 48 limbs, an incidence of 4.16%.

***Type-5*:** The tendon inserted into the calcaneum along with the Achilles tendon in 6 out of

N=48 limbs in which the plantaris was present, an incidence of 12.5%. There was complete n=26 bilateral agenesis of plantaris muscle in 2 limbs of the same male cadaver, an incidence of 4.16%. Table-01 shows the incidences of different types of plantaris tendon insertions.

Table 1: Percentage and frequencies of the different types of insertion

Type of Insertion	*Frequency*	*Percentage*
Type 1	33	68.75%
Type 2	5	10.41%
Type 3	2	4.16%
Type 4	2	4.16%
Type 5	6	12.5%
Total	48	100.0%

Types of Origin

There is not much literature available on the variations of plantaris the muscle in relation with its origin, unless as a case report which brings the attention of especially the orthopedic surgeons for the diagnosis of the patellofemoral pain syndrome
(PFPS). In the present study, it is also encountered a case in which few fibers of the muscle are arising from the lateral patellar ligament bilaterally in a male cadaver. Depending upon the observations six types of origin of the muscle belly are described as follows.

***Type-1*:** The muscle fibers originated from the popliteal surface of the supracondylar ridge just proximal to the origin of the lateral head of the gastrocnemius and some fibers also from oblique a popliteal ligament in 12 out of 48 limbs dissected, an incidence of 25%.

Type-2: The muscle was originated from the following sites, the popliteal surface of the supracondylar ridge, oblique popliteal ligament, and thin bundle of fibers from the posterior
part of the capsule of the knee joint in 14 of 48 limbs, an incidence of 29.16%**.**

Type-3*:* From the popliteal surface of the supracondylar ridge of the femur and from posterior the surface of lateral condyle of the femur in 17 of the 48 limbs, an incidence of 35.41%, the commonest of all types of origin.

Type-4: From Supracondylar ridge, posterior surface of the lateral condyle, posterior part of
the capsule of the knee joint and few slips of muscle fibers originated from the lateral patellar the ligament in 2 of 48 lower limbs, an incidence of 4.16%. In this case, the muscle presented was bilateral, having four sites of origin.

Type-5: From the posteromedial surface of the lateral condyle of the femur only, the shape of the muscle belly is triangular in 2 of 48 limbs, an incidence of 4.16%.

***Type-6*:** Supracondylar ridge and interdigitations with the lateral head of gastrocnemius in the
the right limb of a male cadaver in 1 of 48 limbs, an incidence of 2.08%.

Table 2: Percentage and frequency of the different types of origin

Type of Origin	*Frequency*	*Percentage*
Type 1	12	25.00
Type 2	14	29.16
Type 3	17	35.41
Type 4	2	4.16
Type 5	2	4.16
Type 6	1	2.08
Total	48	100.0

Table 3: The mean values of length, breadth, and thickness of the plantaris muscle and tendon

Sex	*ML cm*	*MB cm*	*MT cm*	*TL cm*	*TB cm*	*TT cm*
Female	7.55	1.35	0.33	30.72	0.31	6.75
Male	8.03	1.64	0.42	33.37	0.30	6.78
Total	7.99	1.62	0.41	33.16	0.30	6.78
SD	2.11	.58	0.28	7.16	0.13	7.24

ML=Muscle length, MB=Muscle breadth, MT=Muscle thickness, TL=Tendon length, TB=Tendon breadth, TT=Tendon thickness, SD=Standard deviation.

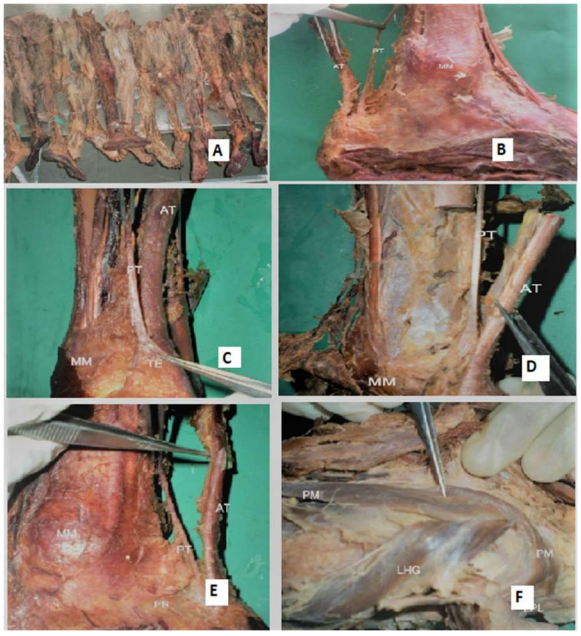

A: few of the specimens dissected for this study; B: type 1 insertion on the left limb in a male cadaver; C: type 2 insertion on the right limb in a male cadaver D: type 3 insertion on the right limb of a male cadaver; E: type 4 insertion on the right limb in a male cadaver; F: type 4 origin on right side of a male cadaver.

Discussion

The plantaris muscle has been given little attention in the reviewed literature. Dassler et al; [1] highlighted the importance of the plantaris muscle both from the anatomical and phylogenetic points of view and from the surgical aspect. Contrary to the concept of vestigial David N Menton in 2000 has focused on the same and with detail, the study concluded that many scientists have ignored the claims of evolutionists regarding vestigial organs, and thus the advance of empirical science has revealed at least one known function for nearly every type of organ, tissue, and cell of the body. [11] The human plantaris belly length is only about one third that of the gastrocnemius, but for any contraction or extension of this PMC (Parallel Muscle Combination), both will undergo similar changes in absolute length. Thus, the plantaris will experience two to three times greater change in both relative length and rate compared to the gastrocnemius. [11] The present study was carried out in n=50 specimens consisting of, n=46 male limbs and n=4 female limbs, n=25 of the left side and n=25 of the right side. There was a total of 4% of bilateral agenesis in a male cadaver, which is coinciding with the study conducted by Kudo T et al; in the Japanese population in the year 1916. [12] The agenesis found by the author was irrespective of sex and lateralization. The highest cases of agenesis in the review literature were by Harvey et al in the year 1983, they studied 658 lower limbs in which they found agenesis of the plantaris muscle in n=126 limbs an incidence of 19.14%. [13] In this study out of n=48 limbs in which the plantaris muscle was present n=33 limbs showed In this study we found the commonest type of insertion i.e. type 1 in which the tendon is directly inserted on the calcaneum medial to the Achilles tendon independently which is 68.75%. When referring to previous authors like Daseler et al; [1] and Schlicht S M [14] in 1992 showed that in at least 80% of their dissected lower limbs the insertion of the plantaris tendon is directly inserted to the calcaneus independent of the tendocalcaneus. In a study conducted by Nayak et al; [15] in 2010 on n=52 lower limbs of n=26 males have observed 36.53% of insertions of the plantaris muscle were independent of the calcaneum. The standard textbooks like Hollinshead 1958 and Gray's Anatomy 40th Edn 2008 have mentioned the length of the muscle belly is 7-10 cm. The total mean length of the muscle belly in our study is 7.99 cms which are like those described by the standard books. The total mean length of the tendon in this study is found to be 33.16cm which is coinciding with the study conducted by Aragao J A et al; [16] in 2010, and with a difference of 2cm with Surat et al; [17] in 2002. As such much literature is not available regarding the measurement of the tendon and the muscle belly, hence the work of the above two authors is taken for comparison. A very small percentage but clinically very important variation was observed in the present study i.e. the muscle originated from four sites those are; From Supracondylar ridge, posterior surface of lateral condyle of femur, posterior part of the capsule of the knee joint, and few slips of muscle fibers from the lateral patellar ligament in 2 of 48 lower limbs, an incidence of 4.16%. This variation is observed bilaterally in one adult male cadaver. This type of origin is also reported only by Freeman A. J et al; [7] in n=5 of n=46 cadaveric knees, an incidence of 10.87% and also n=9 cases of interdigitations with the lateral head of gastrocnemius, an incidence of 19.6% but in this study, it is found to be 2% only. The above types of variations may influence the knee function and stability, consequently allowing the plantaris muscle to have a varying role in knee dynamics, injury, and rehabilitation. The muscles contributing to PFPS (Patellofemoral pain syndrome) include quadriceps, hamstrings, triceps surae, and tensor fascia lata muscles. Common causes of PFPS (Patellofemoral pain syndrome) are the asymmetrical balance of the muscles and tendons attaching to the patella that result in medial or lateral displacement. [18] Hence the plantaris originating from LPL (Lateral patellar ligament) which is the extension of the tendon of the vastus lateralis, will affect the knee dynamics.

Conclusion

The plantaris muscle and its tendon are subject to considerable variation in both the points of origin and insertion. The genesis of the plantaris muscle was seen bilaterally of a male cadaver, an incidence of 4%. Interdigitations with the lateral head of gastrocnemius (2.1%) and extension of few muscle fibers to the lateral patellar ligament (4.16%) encountered in the present study are less frequent but important variations to be considered for differential diagnosis in PFPS [Patellofemoral pain syndrome] related pains. As the plantaris tendon is a tensile and stretchable structure, it is used as a strong reinforcement membrane after suturing the partial rupture of the Achilles tendon. understand the function and its role in producing PFPS and to take more advantage of this slender muscle in surgical grafting and other plastic surgeries.

Conflict of Interest: *None declared*
Source of Support: *Nil*
Ethical Permission: *Obtained*

References

1. Daseler, E.H. and Anson, B.J., The plantaris muscle, an anatomical study of 750 specimens, J. Bone Joint Surgery 1943; 25(4):822–27.
2. Cruveilhier, Jean: Anatomie Descriptive. Tome II. Paris, Bechet Juene, 1834. [French]
3. Le Double AF. Traite des variations du systeme musculaire de l'homme et de leur signification au point de vue de l' anthropologie zoologique. Tome II. Paris, Schleicher Freres. 1897
4. Standring Susan. Gray's Anatomy. The Anatomical Basis of Clinical Practice. 40th Edn. Elsevier Churchill Livingstone, Philadelphia, 2008;1421.
5. Moore KL, Dalley AF, Eds. Clinically Oriented Anatomy. 5th ed. Philadelphia: Lippincott Williams & Wilkins, 2006; 648–649.
6. David. N. Menton. The plantaris and the question of vestigial muscles in man. CEN Tech. J 200; 14(2): 50-53.
7. A. Jay Freeman, Nathan A. Jacobson and Quentin A. Fogg. Anatomical variations of the plantaris muscle and a potential role in patellofemoral pain syndrome: Clinical Anatomy2008; 21:178-181.
8. David M. Kwinter; James P. Lagrew; Julie, Kretzer; Cara Lawrence; Diksha Malik; Megan Mater & Jennifer K. Brueckner. Unilateral Double Plantaris Muscle: A Rare Anatomical variation; Int. J. Morphol 2010;28(4):1097-99.
9. Maayke N. van sterkenburg, Gino M. M. J. Kerkhoffs, Roeland P. Kleipool and C. Neik Van Dijk: The plantaris tendon and a potential role in mid-portion Achilles tendinopathy: an observational anatomical study. J Anat. 2011; 218:336-41.
10. Nayak SR, Krishnamurthy A, V Prabhu, Madhyastha S; Additional tendinous origin and entrapment of the plantaris muscle. Clinics: 2009; 64(1): 67-68.
11. David. N. Menton. The plantaris and the question of vestigial muscles in man. CEN Tech. J 2000; 14(2): 50-53.
12. Kudo, T. On the aponeurosis plantaris In Japanese. Hokuetsu Igakkai Zasshi. 1916; 31:98-107.
13. Harvey FJ, Chu G, Harvey PM. Surgical availability of the plantaris tendon. J Hand Surg Am 8: 1983; 243-247.
14. Schlicht SM, Morrison WA. The plantaris tendon as a tendo-osseous graft. Part I. An anatomical study. J Hand Surg. 1992; 17B:467–470.
15. Nayak SR, Krishnamurthy A, Ramanathan L, Ranade AV, Prabhu LV, Jiji PJ, Rai R, Chettiar GK, Potu BK, Clin Ter. 2010; 161(3): 249-252.
16. Aragao, J. A.; Reis, F. P. Guerra, D. R. & Cabral, R. H. The occurrence of the plantaris muscle and its muscle-tendon relationship in adult human cadavers. Int. J. Morphol 2010;28(1):255-258.
17. Surut. J, Ekamol. T, Weerachai. K, Kimaporn. K. Palmaris longus and plantaris tendon: Anatomical variations and relationship, Srinagarind Med. J. 2002;17(3): 160-163.
18. Callaghan M, Oldham JA. Quadriceps atrophy: To what extent does it exist in patellofemoral pain syndrome? Br J Sports Med 2004; 38:295–299.