

ORIGINAL ARTICLE

Study of Effectiveness of Double Layered Mesh Repair of Incisional Hernias

K Ashok¹, K Rashmi²

1. Associate Professor, Department of General Surgery, Rajiv Gandhi Institute of Medical Sciences and Hospital [RIMS], Adilabad, Telangana State.
2. Senior Resident, Department of Radiology, Nizams Institute of Medical Sciences [NIMS], Hyderabad.

Abstract

Background Recurrent incisional hernias are a common problem for General Surgeon. There is a considerable debate on the optimal treatment of hernias. There is growing evidence in favor of prosthetic mesh treated tension-free repairs of hernias. This study tries to evaluate the effectiveness of double layered mesh repair of incisional hernias. **Methods:** The study was conducted in the Department of General Surgery, Rajiv Gandhi Institute of Medical Sciences and Hospital [RIMS], Adilabad. The patients with incisional hernias were operated from 2008 to 2013 and the cases were followed up post operatively till 2017. A total of 30 patients were treated with this technique. **Results:** The number of patients included in the study were (n=30) male = 5 and female = 25. The age range of the patients was 30 -60 years the average age was 42.73 years. The incidence of incisional hernias according to previous surgeries was Sub umbilical midline were 66.66%, upper midline 6.6%, upper right paramedian 6.6%, Lower right paramedian 13.33% and Pfannenstiel incision 6.6%. The average duration of patient stay in the hospital post operatively ranged from 10- 14 days and Post operative complications including mortality and morbidity and chronic pain was nil. The patients were followed post operatively for 5 years and recurrence was found only in 1 cases (3.3%). **Conclusion:** Tension-free Double layered Mesh repair of incisional hernias is a useful method of treatment. This method is especially suitable for Indian population with lax and flabby abdominal walls. The procedure is relatively safe with no major complications of morbidity and recurrence.

Keywords: Double layered Mesh repair, Incisional Hernias

Address for correspondence: Dr. K Askhok, Associate Professor, Department of General Surgery, Rajiv Gandhi Institute of Medical Sciences and Hospital [RIMS], Adilabad, Telangana State.

Email: ashokkandukari@gmail.com

Introduction

An incisional hernia is defined as a bulge visible and palpable when the patient is standing often requiring support or repair.^[1] Incisional hernias are a common problem for the patients who have undergone abdominal surgeries. The incidence of a hernia after primary surgeries varies from 1 -19%.^[2-4] Majority of incisional hernias recur within 3 years of surgery.^[3] Several predisposing factors have been found to be associated with incisional hernias including, wound infection, age, obesity, the condition of abdominal wall etc. The type of incision and surgical technique, the quality of material used and duration of operations are some of the important causes for recurrences^[5, 6] Tension on

the suture line is considered as one of the main factors of recurrence. The recurrence rates of incisional hernia repair after primary closure of a hernia without the use of the prosthetic material is between 10-50% with considerable morbidity and mortality rates.^[7-9] the cause could be due to incision and re-approximation of the avascular scar tissue and due to excessive tension on the suture line.^[10] Many researchers have found that prosthetic materials when used decrease the tension are well tolerated and associated with remarkably low recurrence rates.^[11-15] The first prosthetic materials were introduced by ancient Greeks.^[16] In 1940 Burke introduced tantalum metal sheets most closely resembled a true prosthesis used today.^[17] Severe complications, patients discomfort and material resorption lead to research into other

materials. Theodore Billroth is credited with envisioning of the current practice of prosthesis repair. In 1857 he proposed that “if we could artificially produce a tissue of the density and toughness of fascia and tendon then the secret of hernia repair would be discovered”.^[18] Nylon was the first plastic prosthetic material used as a suture later woven into mesh prosthesis for hernia repair.^[18] However it lost strength due to hydrolytic digestion and required removal if infected. Later many synthetic materials were developed which were resistant to infection. Usher^[19] introduced the use of Marlex mesh materials, these material showed distinct advantages like ease of use, lack of disintegration with age. Studies conducted on marlex mesh material showed no harm resulting from placing the mesh in the direct contact with omentum or bowel and claimed mechanical advantage to be placed in subfascial position.^[19] The aim of the study was to present advantages of incisional hernia repair using double layered polyester mesh in a tension-free technique as well as to register any post-operative complications.

Materials and Methods

The study was conducted in the Department of General Surgery, Rajiv Gandhi Institute of Medical Sciences [RIMS] Adilabad. The patients with incisional hernias were operated from 2008 to 2013 and the cases were followed up post operatively till 2017. Ethical committee permission for the study was obtained from Institutional Ethical committee. The patients involved in the study were explained in detail about the procedure and long-term follow to be done and only those patients who were ready for long-term follow up were included in the study. Written consent for the participation in the study was obtained from each patient. A total of 30 patients were treated with this technique. Male = 5 and Female = 25, the age range of the patients was 30 -60 years the average age was 42.73 years. Surgical Technique: In all the patients 2nd Generation cephalosporin were used IV upon the induction of anesthesia or earlier and continued for 48 hours after surgery. The skin was scrubbed by using Providine Iodine, draped and the hernia was palpated Identified and a careful incision was given above the sac. In all cases, the incision scar was excised and the sac

was carefully dissected, anatomical layers of anterior abdominal wall dissected. Adhesions were released the surrounding tissue and the fascial margins were dissected free to avoid any injury during reconstruction after removal of protruded part of the sac; the peritoneum was closed with polyglyconate running suture 0-2 Vicryl. A double-layered composite mesh was laid over the rectus sheath and edges are stitched to rectus the mesh was fixed with interrupted non-absorbable Prolene 0-2 suture. Hemostasis was secured closed suction drain was kept and wound closed. The drains were removed on 5th post operative days and suture removed on 8th post operative day.

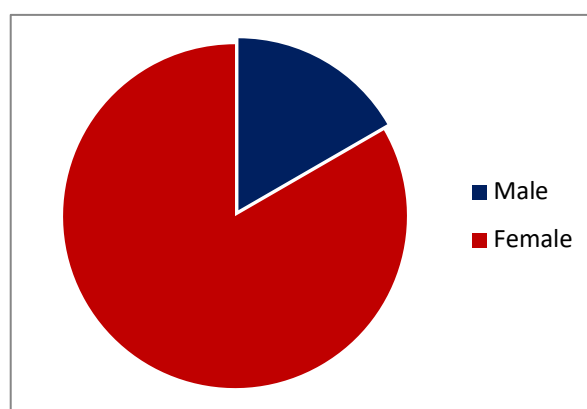
Results

The number of patients included in the study were (n=30) male = 5 and female = 25. The age range of the patients was 30 - 60 years the average age was 42.73 years. The demographic profile of the patients included and distribution is shown in table 1.

Table1: Demographic profile of the patients

Age	Female	Male	Total %
30- 35	6	1	7 (23.34%)
36-40	3	0	3 (10 %)
41-45	8	1	9 (30%)
46-50	4	2	6 (20%)
51-55	2	1	3 (10%)
56-60	2	0	2 (6.67%)
Total	25	5	30 (100%)

Figure 1: sex wise distribution of cases



The incidence of incisional hernias according to previous surgeries were Sub umbilical midline

were 66.66% (20), upper midline 6.6% (2), upper right paramedian 6.6% (2), Lower right paramedian 13.33% (4) and Pfannenstiel incision 6.6% (2). The average duration of patient stay in the hospital postoperatively ranged from 10- 14 days and Postoperative complications including mortality and morbidity and chronic pain was nil. The patients were followed postoperatively for 5 years and recurrence was found only in 1 cases (3.3%).

Table 2: The incidences of incisional hernias according to the incision given in primary surgeries

SL. No	Previous surgeries	Number	percentage
1	Sub umbilical midline	20	66.67%
2	Upper midline	2	6.67%
3	Upper right Paramedian	2	6.67%
4	Lower paramedian	4	13.33%
5	Pfannenstiel incision	2	6.67%
Total		30	100

Discussion

Incisional hernias usually are present an asymptomatic bulge in the abdominal wall noticed by the patients. 60% of patients with hernias do not have any symptoms they may be sometimes detected by the surgeon on the complete physical examination. Pain is sometimes present due to rigorous physical activities in some individuals. The primary surgical incision that causes incisional hernias is midline incision as compared to transverse incisions. [4, 8, 20] In our study we found that the incidence of incisional hernia of sub umbilical midline region in 66.67% of cases. Usually, primary surgical incisions of midline are closed by simple closure techniques using continuous or interrupted sutures to approximate the edges of the fascial defect. However this technique may lead to excessive tension and subsequent wound dehiscence due to tissue ischemia and cutting of sutures through the tissues [4, 8, 21] use of prosthetic materials for hernia repair have gain popularity since 1950. The prosthetic

materials are used to reinforce the fascia or to bridge the existing defect between the borders of abdominal walls and aponeurosis. [22] The ideal mesh for prosthetic repair is a matter of debate because of several advantages and disadvantages associated with each of it. One of the important disadvantages of prosthetic is that a large peritoneal defect and direct contact between the mesh and intra-Abdominal organs might result in adhesion formation and mechanical bowel obstruction or fistula formation. [23] In a study by GD Leber et al; [24] looking at long-term complications associated with prosthetic repair of an incisional hernia found that multifilament polyester mesh has a significantly higher number of complications per patient. In our study, we used a double-layered composite mesh and we had reasonable success rates and there was only one case of recurrence (3.3%). We also did not have any significant wound infections, morbidity and mortality post operatively after 5 years of follow up. RW Luijendijk et al; [8] studying comparison of mesh repair and suture repair of an incisional hernia found that mesh repair is superior to suture repair with regard to the recurrence of a hernia, regardless of the size of a hernia. It appears that the successes of hernia repair not only depends on the type of material used, but also depends on the selection of cases for repair, surgeon's skill, post-operative care and follow up. In our study we had planned and repaired hernias with double layered mesh and the repair was completely tension free. That is one of the reasons for the high success of mesh repair of incisional hernias in our study.

Conclusion

It can be concluded that tension-free Double layered Mesh repair of incisional hernias is a useful method of treatment. This method is especially suitable for Indian population with lax and flabby abdominal walls. The procedure is relatively safe with no major complications of morbidity and recurrence.

Conflict of Interest: None declared

Source of Support: Nil

Ethical permission: Obtained

References

1. Niggebrugge AHP, Trimobos JB, Hemans J, et al; Influence on abdominal wound closure technique on complications after surgery: A randomized study. *Lancet* 1999; 353:1563-67.
2. Kollar R, Miholic J, Jaki J. Repair of incisional hernias with expanded polytetrafluoroethylene. *Eur J Surg* 1997;163:261-66.
3. Chrysos E, Athanasakis E, Saridaki Z et al; Surgical repair of incisional ventral hernias tension-free technique using prosthetic materials. *Am Surg* 2000;66:679-82.
4. Millikan KW. Incisional hernia repair. *Surg Clin North Am* 2003; 83: 1223-34.
5. Huock J, Rypin E, Sarfeh J, Juler, G.L., Shimoda, K.J. Repair of an incisional hernia. *Surg Gynecol Obstet* 1989; 169:397-99.
6. Petersen S, Henke G, Freitag M, Faulhaber A, Ludwig K. Deep prosthesis infection in incisional hernia repair: predictive factors and clinical outcome. *Eur J Surg* 2001; 167(6):453-57.
7. Leber GE, Garb JL, Alexander AI, Reed WP. Long-term complications associated with prosthetic repair of incisional hernias. *Arch Surg* 1998;133(4):378-82.
8. Luijendijk RW, Hop W, Van den Tol M, DCD de Lange et al; A comparison of suture repair with mesh repair for an incisional hernia. *N End J Med* 2003; 17(10):1546-51.
9. Rubio P use of double-layered expanded PTFE to repair giant ventral hernias. *Contempsurg* 1995; 46:189-92.
10. Gorge E, Ellis H. The results of incisional hernia repair: A twelve year review. *Ann R Coll Surg Engl* 1986; 68: 185-87.
11. Koller R, Miholic J, Jaki J. Repair of incisional hernias with expanded polytetrafluoroethylene. *Eur J Surg* 1997;163:261-6.
12. Stoppa R. The treatment of complicated groin and incisional hernias. *World J Surg* 1989;13(5):545-54.
13. Deligiannidis N, Papavasiliou I, Sapolidis K, Kesisoglou I, Papavramidis S, Gamvros O. The use of three different mesh materials in the treatment of abdominal wall defects. *Hernia* 2002;6:51-5.
14. Decherney AH, di Zerega GS. Clinical problem of intraperitoneal post-surgical adhesion formation following general surgery and the use of adhesion prevention barriers. *Surg Clin North Am* 1997;77:671-88.
15. Zieren J, Paul M, Osei-Agyemang T, Maecker F, Muller JM. Polyurethane-covered dacron mesh versus polytetrafluoroethylene Dual Mesh for intraperitoneal hernia repair in rats. *Surg Today* 2002;32:884-86.
16. Goepel R. The closure of break-up walls by means of healing of prepared silver wire nets. *Verh Deutsch GesChir* 1900;9:174-79.
17. Burke GL. Corrosion of metals in tissues; and introduction to tantalum. *Can Med Assoc J* 1940;43:125-28.
18. Yilmaz Bilsel, Ilker Abci. The search for ideal hernia repair; mesh materials and types. *International Journal of Surgery* 2012;10: 317-21.
19. Usher FC. Use of Marlex mesh in the repair of incisional hernias. *Am Surg.* 1958; 24:969-74.
20. Carlson MA, Ludwig KA, Candon RE. A ventral hernia and other complications of 1000 incisions. *South Med J* 1995; 88(4):450-53.
21. Gerge CD, Ellis H. The results of incisional hernia repair a twelve-year review. *Ann R Coll Surg Engl* 1986;68(4):185-87.
22. Reingruber B, Kastl S, Stremmel C, Peter DK; Incisional Hernia repair: tensiometry for the selection of the appropriate procedure. *Eur J Surg* 2001; 167 (12):903-08.
23. Scott-Coombes DM, Vipond MN, Thompson JN. General surgeons' attitudes to the treatment and prevention of abdominal adhesions. *Ann R Coll Surg Engl* 1993;75:123-28.
24. Geoffrey E. Leber, Jane L. Garb, Albert I. Alexander, MD; William P. Reed, Long-term Complications Associated With Prosthetic Repair of Incisional Hernias. *Arch Surg.* 1998;133:378-82.