


CASE REPORT

DENTISTRY



Journal of Contemporary Medicine and Dentistry

www.jcmad.com

ISSN [P-2347-4513]
ISSN [O-2349-0799]
Year: 2022, Volume: 10
Issue: 2, p:10 - 12

Attribution-NonCommercial 4.0 International (CC BY-NC 4.0)

Selective Root Retreatment with 14 Month Follow-Up: Case Report

Ežerskytė Gita

Lithuanian University of Health Sciences

Abstract

Selective root retreatment is a novel method and more preserving of tooth tissue during retreatment of the root canal than classic root canal retreatment. The aim of this case report is to consider selective root retreatment approach.

Keywords: selective root retreatment, periapical disease, metal cast post

Address for correspondence: Dr. Gita Ežerskytė, DDS, Lithuanian University of Health Sciences. Lithuania.

Date of Acceptance: 01/06/2022

Introduction

After unsuccessful initial endodontic treatment when occurred periapical lesions, non-surgical or surgical retreatment of dental canals may be performed. Nonsurgical retreatment is more conducive long-term outcome than endodontic surgery. ^[1] Selective nonsurgical retreatment is novel approach, however an uncommonly used. Selective treatment is one of treatment method, which preserving tooth tissue. ^[2] The aim of this case report is to consider selective root retreatment approach.

Case Report

A 20-year-old male was sent with referral from another clinic to The Hospital of Lithuanian University of Health Sciences Kaunas Clinics Department of Dental and Oral Pathology for endodontic retreatment. Medical history was collected. The patient complained of recurrent toothache on the right side of the lower jaw, which lasted about half a year. Pain resolved after taking painkillers. However, the pain recurred after a few days. The patient stated that the dental root canal treatment and tooth prosthetics was performed two years ago. A clinical examination was performed. Right first molar was with a metal-ceramic crown and the

tooth did not show sensitivity to percussion and palpation. Periodontal pockets and the tooth mobility we did not detected. Dental radiograph showed periapical lesion surrounding mesial root and a large metal cast post and core in distal root, which occupied 1/2 the length of the root and it cover the entire area of the pulp chamber. (Fig. 1, 2) Before the canal retreatment, the patient was sent a prosthetic dentist to remove the metal-ceramic crown and to place a temporary crown. Reasonable risks were discussed with the patient and chose selective root retreatment approach. ^[2]

On the next visit the patient came with a temporary crown on the right side of the lower jaw first molar. The tooth isolated with rubber dam, temporary crown was removed and the metal post we divided into two parts buccolingual direction with a crosscut carbide bur (557; Densply Sirona, USA). A temporary crown with a temporary dental cement Temp-Bond™ (KaVo Kerr, USA) was applied.

During the third visit of the dental mesial canals was performed using a dental microscope and following ESE guidelines. Gutta-percha was removed using a rotary endodontic file Protaper Gold to F4 (Denply Sirona, USA). Canals working length was determined and irrigated with sodium hypochlorite 2,5%, sterile saline solution and EDTA 17%. Canals was obturated

with AH PLUS sealer and thermoplastic gutta-percha (Densply Sirona, USA). Postoperative radiograph was recorded. (Fig. 3, 4) Follow-up visit after six months. The patient had no complaints. Tooth was with a temporary crown. Tooth did not show sensitivity to percussion and palpation, no tooth mobility and periodontal pockets. Bone healing was seen on the repeated periapical radiograph. (Fig. 5) Follow-up after

14 months showed complete bone healing on a periapical radiograph associated with the mesial root. (Fig. 6) Tooth still was with a temporary crown and the patient had no symptoms. Tooth did not show sensitivity to percussion and palpation, no tooth mobility and periodontal pockets. After last visit we sent the patient to replace the temporary crown to a permanent one.

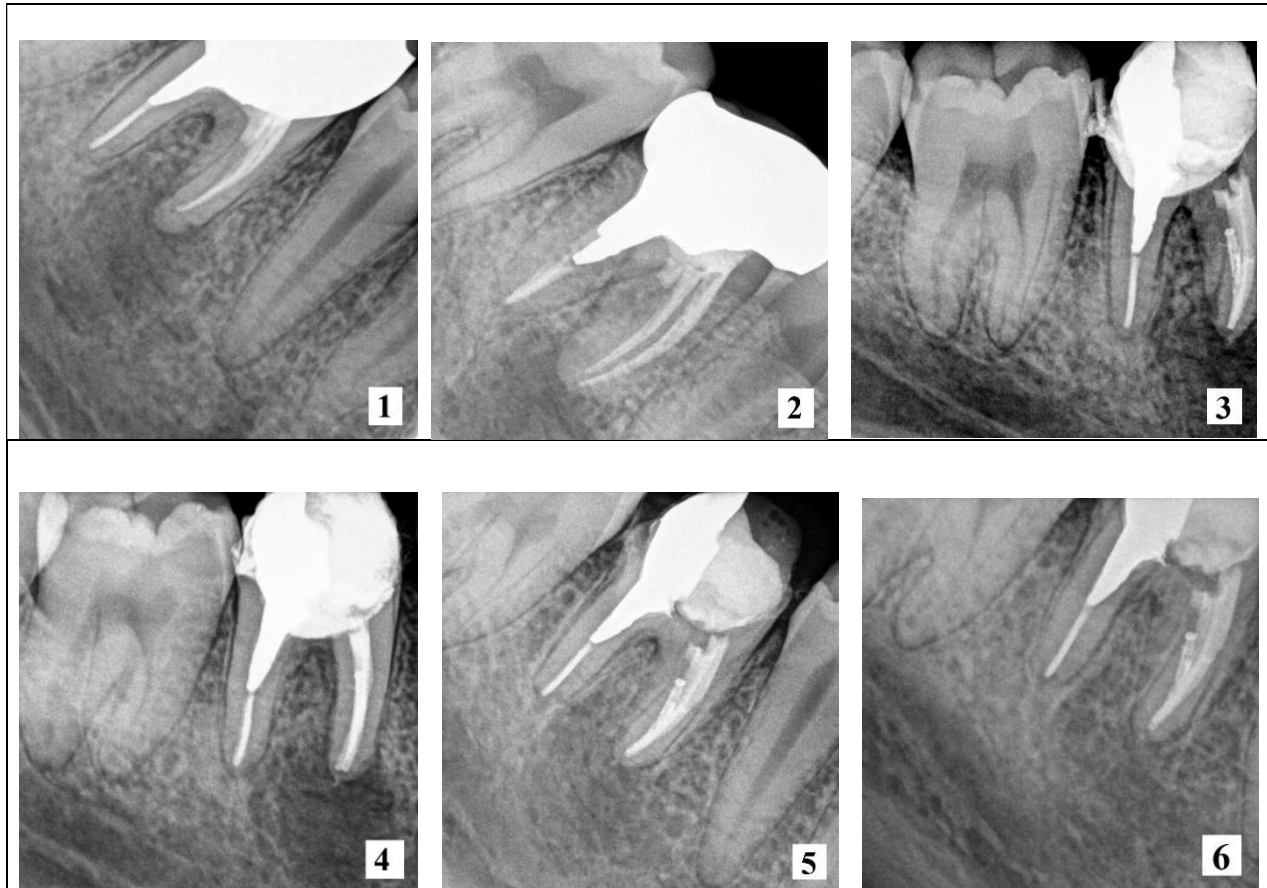


Fig. 1, 2. Preoperative periapical radiographs the right side of the lower jaw first molar. **Fig. 3, 4.** Postoperative radiograph the right side of the lower jaw first molar. **Fig. 5.** Follow-up after 6 month. **Fig. 6.** Follow-up after 14 months.

Discussion

The success rate of primary endodontic treatment is 86 to 98 percent ^[3] and endodontic retreatment is 69,03 percent. ^[4] The success of treatment may be affected by bacteria remaining in the root canals after treatment ^[5,6] or iatrogenic errors. ^[7] We didn't know why the initial treatment was unsuccessful in this case.

In this case we had three options of retreatment approach: complete endodontic canal retreatment with cast post and core removal;

selective root canal retreatment without cast core removal and surgical endodontics. We chose selective root canal retreatment approach. However, the best method hasn't developed yet. Treatment have to be selected appropriate for each situation. It is still unclear, surgical endodontic or non-surgical treatment approach is more successful. ^[8] A systemic review by Torabinejad et al concluded that nonsurgical retreatment more conducive long-term outcome than endodontic surgery. ^[1] Selective root retreatment is more preservation of tooth tissue

than classic root canal retreatment.^[2] This is the reason why we chose this particular method of treatment. We did not remove the metal cast post from the distal root, due to the potential risk of root cracking and performed retreatment of mesial root. The result of proper endodontic retreatment is healed periapical lesion surrounding mesial root after 14 month follow-up period. During the follow-up visits the patient had no complaints. Tooth was with a temporary crown and did not show sensitivity to percussion and palpation, no tooth mobility and periodontal pockets we did not detected. Whereas the patient had no complaints after last visit and the bone was healed, we sent the patient to replace the temporary crown to a permanent one. Few sources write about the selective dental root canals treatment. Only a few research studies have been performed. Therefore, further studies with larger samples are needed.

Conclusion

The selective root canal retreatment performed in this case report was successful and the tooth was preserved. At least one year of follow-up is required to make sure that the periapical lesion is healing.

Conflict of Interest: None
Source of support: Nil
Ethical Permission: Obtained

References

1. Torabinejad M, Corr R, Handysides R, Shabahang S. Outcomes of nonsurgical retreatment and endodontic surgery: a systematic review. *J Endod* 2009 Jul; 35(7):930-7.
2. William J Nudera. Selective Root Retreatment: A Novel Approach. *J Endod* 2015 April; 41(8):1382-8.
3. Friedman S, Abitbol S, Lawrence HP. Treatment outcome in endodontics: the Toronto Study. Phase 1: initial treatment. *J Endod* 2004 March; 2003;29:787-93.
4. Gorni GMF, Gagliani MM. The outcome of endodontic retreatment: a 2-yr follow-up. *J Endod* 2004 Jan; 30(1):1-4.
5. Sakamoto M, Siqueira JF Jr, Rôças IN, Benno Y. Molecular analysis of the root canal microbiota associated with endodontic treatment failures. *Oral Microbiol Immunol* 2008 Aug; 23(4):275-81.
6. Qian W, Ma T, Ye M, Li Z, Liu Y, Hao P. Microbiota in the apical root canal system of tooth with apical periodontitis. *BMC Genomics*. 2019; 20(Suppl 2): 189.
7. Aga N, Thakur MK, Agwan MAS, Eisa M, Habshi AY, Azeem S. Evaluation of Quality of Endodontic Re-Treatment and Changes in Periapical Status. *J Pharm Bioallied Sci*. 2021 Jun; 13(Suppl 1): S379–S382.
8. Del Fabbro M, Corbella S, Sequeira-Byron P, Tsesis I, Rosen E, Lolato A, Taschieri S, and Cochrane Oral Health Group.. Endodontic procedures for retreatment of periapical lesions. *Cochrane Database Syst Rev* 2016 Oct; 2016(10): CD005511.